



Interdisciplinary treatment of patient with gummy smile. Case report

Tratamiento interdisciplinario de paciente con sonrisa gingival: Reporte de un caso

Cintia Villaseñor Espín,* María del Carmen López Buendía§

ABSTRACT

Introduction: A comprehensive, inter-disciplinary treatment of the mouth involves the following aspects: assessment of facial characteristics and muscle activity as well as existing relationship between visible dentition and soft tissues to improve patients' aesthetics and function. There are some physiological and/or pathological conditions which result in excessive exposition of the gums. This causes a negative appearance and limits facial expression. Altered or delayed eruption is one of the main causes of gummy smile. In restorative procedures, crown elongation is considered a very valuable surgical technique. This technique has the aim of lengthening the size of the clinical crown. As part of an inter-disciplinary treatment, dental implants represent an option in cases where there are missing teeth. **Clinical case:** 56 year old female patient attended the Implantology and Periodontics Department complaining of not liking the appearance of her teeth and smile. Clinical exploration disclosed thick biotype, irregular gingival margins, short and uneven clinical crowns, missing teeth as well as decreased vertical dimension. X ray assessment revealed bony margin at the level of enamel and cement junction. Emitted diagnosis was: Altered Passive Eruption. Based on diagnostic wax-up and after consultation with the Oral Prosthesis Department, treatment selected was crown elongation with bone surgery in upper and lower front teeth, implant placement in areas of teeth 36 and 46 as well as rehabilitation following the Captek system. **Results:** Results were favorable. Dentofacial and dental-periodontal harmony were achieved, as well as function, aesthetics and the patient's satisfaction.

Key words: Gummy smile, altered passive eruption, crown lengthening, dental implants.

Palabras clave: Sonrisa gingival, erupción pasiva alterada, alargamiento de corona, implantes.

RESUMEN

Introducción: Un tratamiento integral bucal involucra la evaluación de las características faciales, actividad muscular, y la relación entre la dentición visible y los tejidos blandos para mejorar función y estética del paciente. Algunas condiciones fisiológicas y/o patológicas resultan en la exposición excesiva de la encía ocasionando un aspecto negativo, limitando la expresión facial. Una de las principales causas de una sonrisa gingival es la erupción pasiva alterada o retardada. El alargamiento de corona es una técnica quirúrgica muy valiosa para procedimientos restaurativos, diseñada para aumentar el tamaño de la corona clínica. Como parte de un manejo interdisciplinario, los implantes dentales son una opción de tratamiento cuando existen dientes ausentes. **Caso clínico:** Paciente femenina de 56 años acude al Departamento de Periodoncia e Implantología porque no le gusta la apariencia de sus dientes ni su sonrisa. A la exploración clínica se observa biotipo grueso, márgenes gingivales irregulares, coronas clínicas irregulares y cortas, ausencia dentales y dimensión vertical disminuida. Radiográficamente el margen óseo se encuentra a nivel de unión cemento esmalte. El diagnóstico es erupción pasiva alterada. Con el Departamento de Prótesis Bucal y con base al encerado diagnóstico se deciden hacer alargamientos de corona con cirugía ósea en dientes anteriores superiores e inferiores, colocación de implantes en zona de dientes 36 y 46 y rehabilitación protésica con el sistema Captek. **Resultados:** Los resultados fueron favorables, se logró obtener armonía dentofacial y dentoperiodontal, así como función, estética y satisfacción en la paciente.

www.medigraphic.org.mx

INTRODUCTION

A smile is the most common facial expression to display satisfaction, joy or happiness. Some physiological and/or pathological conditions result in a displeasing excessive exposition of the gums. This alteration bears a negative repercussion on the individual's appearance since it alters the spontaneity of facial expression.

* Graduate, Periodontics and Implantology Specialty.

§ Teacher at the Periodontics and Implantology Specialty.

Graduate School, National School of Dentistry, National University of Mexico (UNAM)

This article can be read in its full version in the following page:
<http://www.medigraphic.com/facultadodontologiaunam>

In our times, patients seek aesthetic dental treatments, to this end, new surgical and prosthetic techniques have been developed with the purpose of achieving desired results.¹

Aesthetic dentistry is not only limited to restoration of damaged or absent teeth, it is also geared to prevention and reconstruction of adjacent soft tissue architecture. In order to achieve aesthetic results, many cases require inter-disciplinary treatment combining several procedures.^{2,3} In those cases where aesthetics are involved, surgical alterations of the dental-gingival system can be carried out so as to create an appropriate situation, especially in gummy smile cases.

Determination of gummy smiles causes is of paramount importance. A mistake at this stage could elicit unsatisfactory results as well as complications such as root exposition.

Etiology of excessive gum exposition of gummy smile can be: 1) Short lip length, 2) Excessive lip activity, 3) Length of short clinical crown, 4) Altered passive eruption, 5) Dental-alveolar extrusion, 6) Excessive maxillary vertical dimension.⁴

In order to define the concept of altered passive eruption, we must first review the concepts of eruption process: *active eruption* is the tooth's occlusal movement up to the point when it reaches its antagonist. *Passive eruption* features the apical displacement of the dentogingival junction when the tooth reaches its antagonist, the gingival sulcus and the junction epithelium are over the enamel and the clinical crown corresponds to approximately 2/3 of the anatomical crown.^{2,5,6}

From the histological perspective, passive eruption is divided into four stages: I) Dentogingival junction is located in the enamel. II) Dentogingival junction is located in the enamel as well as the cement. III) Dentogingival junction is entirely located in the cement, extending in coronary direction to the cement-enamel junction (CEJ). IV) Dentogingival junction is located in the cement; there is root exposition as a result of a continuous migration. This can be considered a pathological state rather than a physiological state.^{2,5,6}

When the dentogingival junction remains in Stage I, even after adulthood sets in, an event called *altered passive eruption* takes place. This in turn, can be classified in the following fashion: **Type I** the gingival margin is in a coronary position with respect to CEJ with a wide strip of inserted gum. **Type II** the gingival margin is in a coronary position with respect to CEJ with a normal strip of inserted gum. In turn, it can be sub-classified into **A**: distance from alveolar

crest to CEJ 1.5-2.0 mm and **B**: alveolar crest at the level of CEJ.

Aesthetic crown lengthening for the four types of altered passive eruption is significantly different. Type I, subgroups A and B are the most prevalent.

Ability to achieve proper treatment in gummy smile cases is limited when faced to excessive maxillary growth. This must be treated with orthognathic surgery.⁹

Crown lengthening can be defined as the surgical procedure designed to increase extension of the clinical crown aiming to achieve functional or aesthetic purposes. The gingival margin is placed in apical position and/or bone can be removed. It can be accompanied by orthodontic movements.¹⁰

Surgical techniques with prosthetic aims have the objective to improve functional and aesthetic aspects as well as to retrieve gingival symmetry and harmony. One of the main factors to reach satisfactory results is visualization of final outcome before initiating any type of treatment. The first step is to determine the size of the clinical crowns, the position of lips at rest, as well as the position of the lower lip when smiling.²

As part of inter-disciplinary treatment, placement of dental implants is a prosthetic treatment option for those cases where there are missing teeth, to achieve rehabilitation with either fixed or removable prostheses. Endo-osseous dental implants are devices surgically placed into the alveolar ridge and/or basal bone to substitute missing or damaged anatomical parts, or to stabilize one or more periodontally compromised teeth. All these procedures are performed to achieve functional, therapeutic and/or aesthetics aims.¹⁰

Table I. Classification and treatment of altered passive eruption.^{7,8}

Type		Treatment
I	A	Gingivectomy with gingivoplasty
	B	Gingivectomy, gingivoplasty Bone resection to establish proper biological thickness
II	A	Crown lengthening with apically displaced flap
	B	Crown lengthening with apically displaced flap Bone resection to establish proper biological thickness

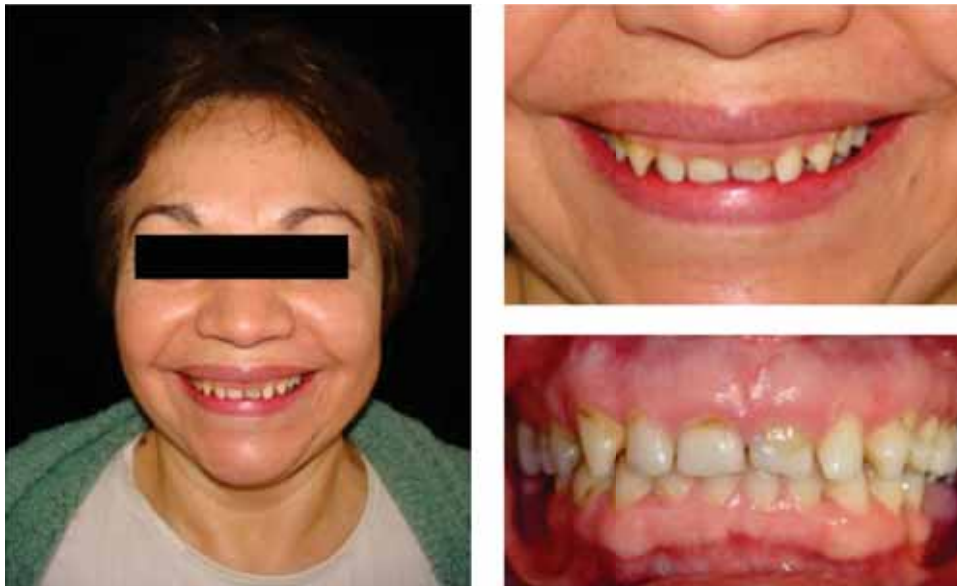

Figure 1. Initial clinical characteristics.

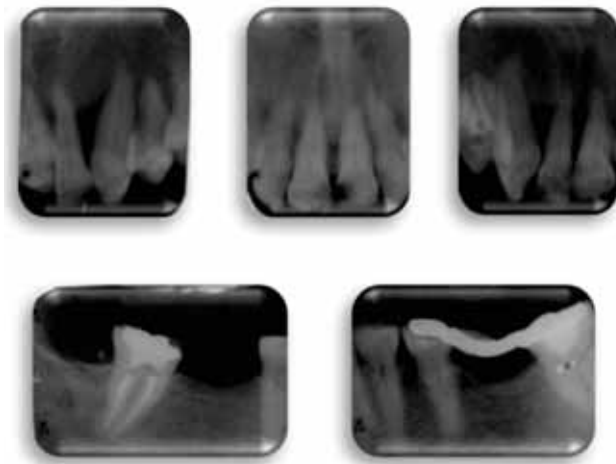


Figure 2. Initial radiographic characteristics.

CLINICAL CASE

56 year old Mexican female patient. Patient suffering from hypertension attended the Graduate and Research Division to receive dental treatment on account of not liking her smile or teeth. The patient was admitted at the Periodontics and Implantology Department. Clinical observation revealed facial symmetry, high smile (gummy smile) thick biotype, irregular gingival margins, short clinical crowns, irregular dental morphology, missing teeth, ill-adjusted restorations, as well as decreased vertical

dimension.^{7, 11, 12} X-ray examination revealed bony margin at the level of cement enamel junction in the anterior area. Patient informed of alveolus preservation in the area of tooth 46. Once gingival enlargement due to drugs intake was discarded, diagnosis emitted was Altered Passive Eruption **Type II-B** (Figures 1 and 2).

After consultation with Oral Prosthesis and Implantology Departments, a diagnostic wax-up was performed. Designed treatment plan was the following: 1) periodontal phase 1, 2) crown elongations with bone resection in upper and lower anterior teeth, 3) placement of bone -integrated implants in areas of teeth 36 and 46, 4) Root canal treatment in teeth 17-14, 11, 21, 26, 37, and 5) Prosthetic rehabilitation in all teeth with Captek system.

Once treatment plan was accepted, and based on previous diagnostic wax-up (Figure 3) an acrylic surgical guide was manufactured (Figure 4) so as to conduct crown lengthening with bone surgery in teeth 13-23 and 33-43. The amount of removed bone tissue was based upon the sum of the dentogingival complex size with the new length of the tooth. This was aimed at establishing a healthy periodontium based on aesthetics, function and structure needed for proper rehabilitation.^{2,3}

Four months later, provisional teeth were placed over the gingiva, so as not to invade biological thickness during healing phase.¹³ Six months later provisional devices were placed sub-gingivally (Figures 5 and 6).

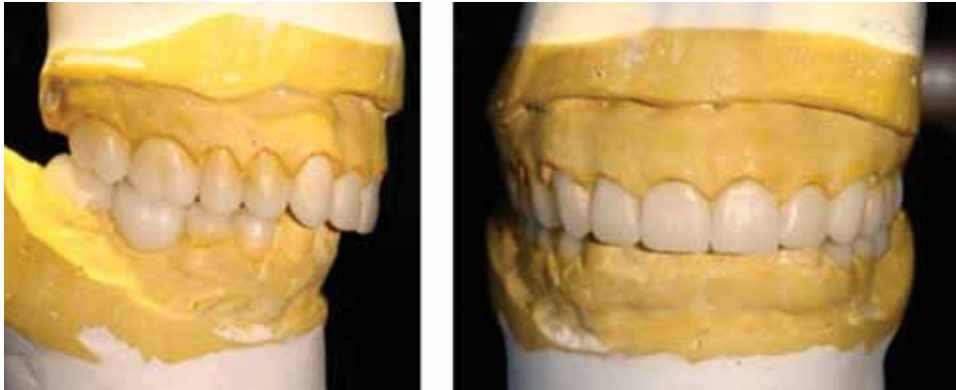


Figure 3. Diagnostic wax-up.

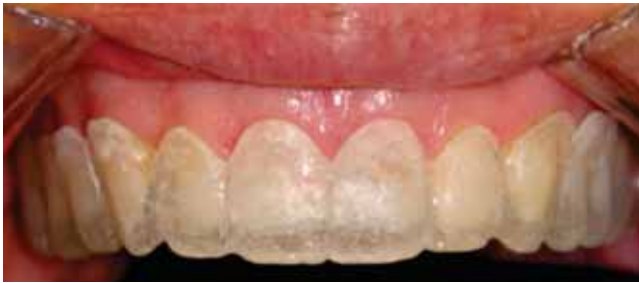

Figure 4. Acrylic surgical guide.

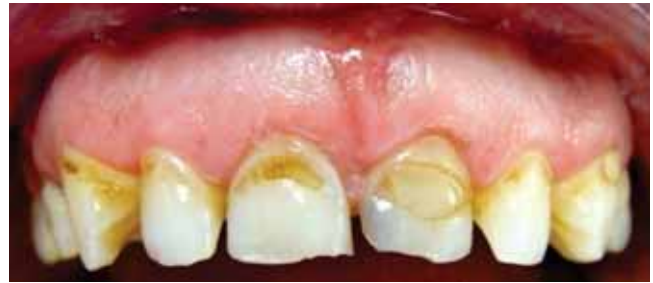

Figure 5. Healing after three months.

At a later point, implants were placed in one single phase (Straumann® SP 4.8 mm WN SLA) in areas of teeth 36 and 46 (Figure 7).

Final impressions were taken eight months after crown elongations and four months after implant placement. Prosthetic rehabilitation was achieved with Captek System.

RESULTS

Results were favorable. After final restoration cementation in teeth and implants, regular gingival margins were achieved as well as increase of clinical crown size and vertical dimension. Stability of soft and hard tissues was equally achieved.

Implants individually replaced missing teeth. Patient was satisfied since, when smiling, no excessive amount of gums could be perceived, therefore, functional and aesthetic expectations were met (Figures 8, 9 and 10).

DISCUSSION

Successful combination (amalgamation) of periodontal and restorative procedures, in teeth as

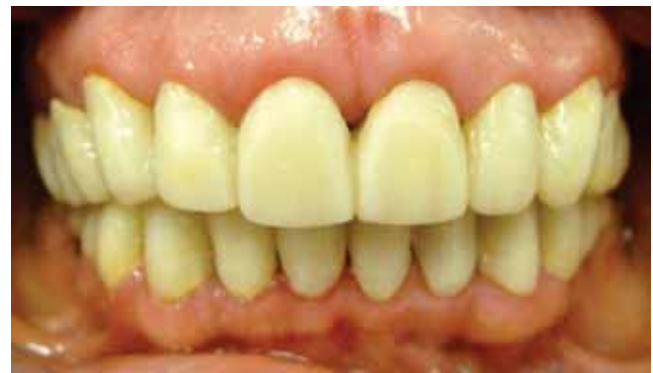

Figure 6. Provisional dentures. Clinical characteristics six months after lengthening the crowns.



Figure 7. Dentoalveolar X-rays of implants placed in areas of teeth 36 and 46 (Strauman® SP WN Ø4.8 12 mm).

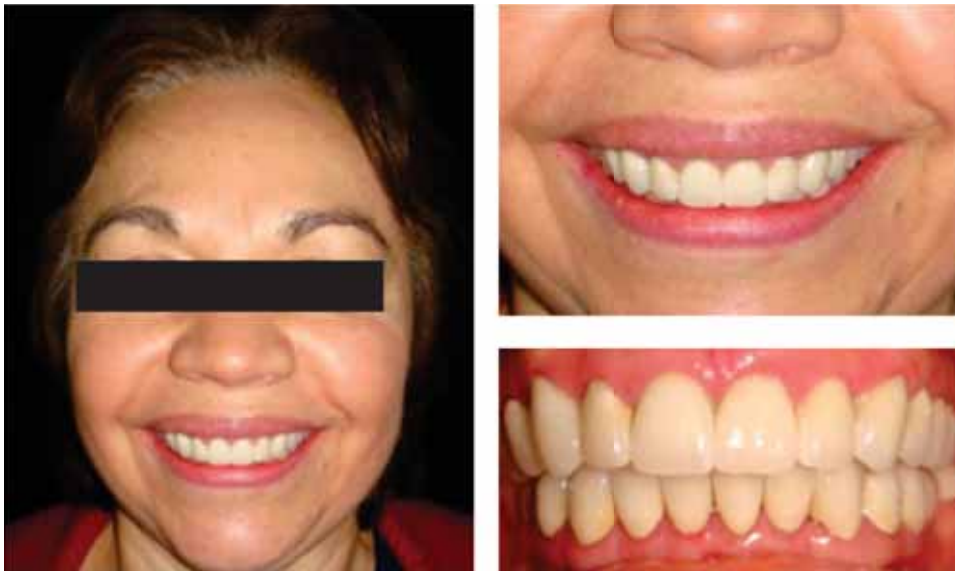

Figure 8. Final clinical characteristics.

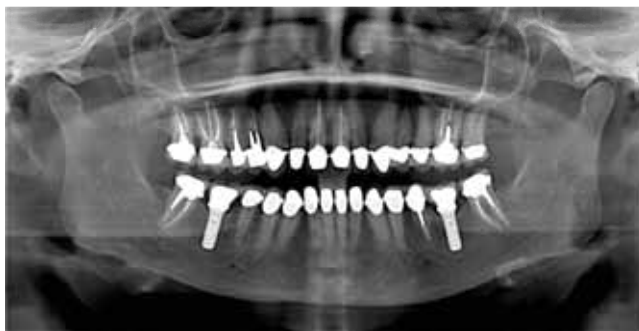

Figure 9. Final panoramic X-ray.

well as implants, require knowledge and application of biological and mechanical principles.¹⁴

Recognition of a patient with altered passive eruption is an ill-documented situation. Etiology is multi-factorial, therefore, dental, skeletal and genetic factors must be considered so as to render diagnosis and treatment. Differential diagnoses could be gingival fibromatosis, drug-induced enlargement, or some sort of physiological alteration.

From the periodontal, restorative and aesthetic standpoints, absence of conditions such as bleeding, periodontal pockets or bone loss must be ascertained. The bone-alveolar bone ration must be identified before initiation of prosthetic treatment. In necessary cases, bone surgery must be performed

with an apically positioned flap so as to establish proper biological thickness and thus preserve periodontal health.⁶ In cases when sub-gingival margins are required, these must be 0.5 mm within the sulcus so as to avoid impinging on the biological thickness.^{14,15}

CONCLUSIONS

Inter-disciplinary treatment combines aesthetic and biological principles, as well as prosthetic and surgical techniques essential to the success of a patient's comprehensive treatment. Excessive gum exposition, or gummy smile, can be solved with crown lengthening and bone surgery. Nevertheless, it is of utmost importance to determine the causes, since an error at this stage could elicit unsatisfactory results as well as complications. Proper location of the restoration margin with respect to the alveolar bone, can be the most important parameter to ensure long term success and health. Bone integrated implants are an excellent treatment option to replace missing teeth. Restorative dentistry faces the challenge of creating ideal situations as well as preserving periodontal health at the gum-restoration phase be it in teeth or implants.

Inter-disciplinary handling of patients is the best way to arrive to an adequate diagnosis and treatment plan. This will elicit favorable results as well as being satisfactory to the patient as well as the clinician.

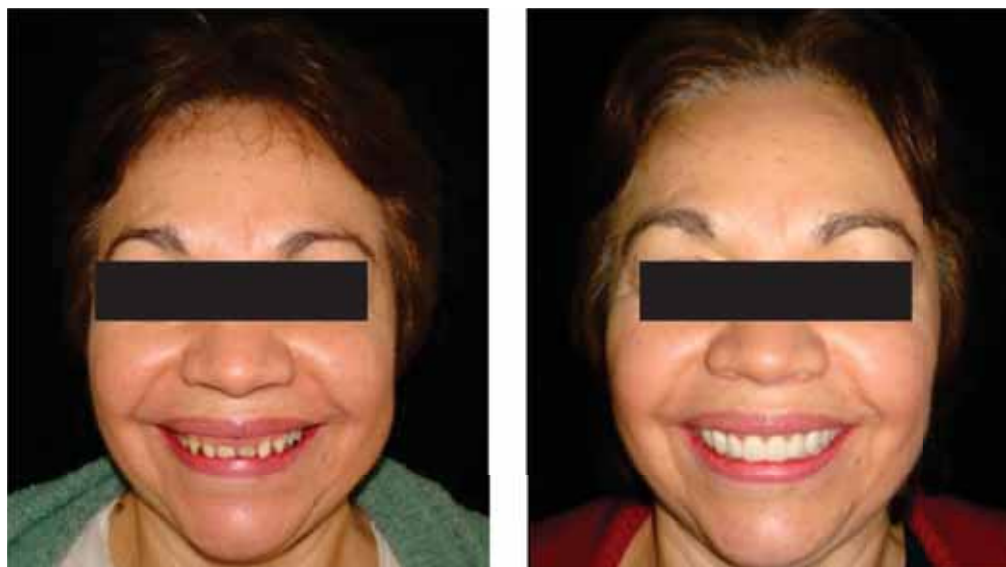

Figure 10. Comparison before and after treatment.

REFERENCES

1. Takei HH et al. Surgical crown lengthening of the maxillary anterior dentition: Aesthetic considerations. *Pract Periodont Aesthet Dent* 1999; 11 (5): 639-644.
2. Enríquez. Estética en periodoncia y cirugía plástica periodontal. Ed. AMOLCA. Brasil. 2006; 1, 11, 12.
3. Spears F et al. Interdisciplinary management of anterior dental esthetics. *JADA* 2006; 137: 160-169.
4. Robbins W. Differential diagnosis and treatment of excess gingival display. *Pract Periodont Aesthet Dent* 1999; 11 (2): 265-272.
5. Dolt A, Robbins W. *Altered passive eruption: An etiology of short clinical crowns*. Quintessence Int 1997; 28: 363-372.
6. Weinberg M, Eskow R. An overview of delayed passive eruption. *Compendium Dent Edu* 2000; 21 (6): 511-520.
7. Levine R, McGuire M. The diagnosis and treatment of the gummy smile. *Compendium* 1997; 18 (8): 757-764.
8. Coslet JG, Vanarsdall R, Weisgold A. Diagnosis y clasificación de delayed passive eruption of the dentogingival junction in the adult. *Alpha Omega* 1977; 70 (3): 24-28.
9. Kao R et al. Esthetic crown lengthening: Appropriate diagnosis for achieving gingival balance. *J Calif Dent Assoc* 2008; 36 (3): 187-191.
10. Glossary of Periodontal Terms. 2001. 4^a ed. The American Academy of Periodontology. Chicago, USA.
11. Tjan A et al. Some esthetics factors in smile. *J Prosth Dent* 1984; 51 (1): 24-28.
12. Jorgensen M, Nowsari H. Aesthetic crown lengthening. *Periodontology* 2001; 27: 45-58.
13. Camargo P, Melnick P et al. clinical crown lengthening in the esthetic zone. *J Calif Dent Assoc* 2007; 35 (7): 487-498.
14. Goldberg, P. y cols. Periodontal considerations in restorative and implant therapy. *Periodontology* 2000; 25, 2001, 100-109.
15. Kois, J. The restorative-periodontal interface: biological parameters. *Periodontology* 2000; 11: 1996, 29-38.

Mailing address:

María del Carmen López Buendía

E-mail: cdmclopezb@hotmail.com