



Enalapril-induced lichenoid reaction. Clinical case report

Reacción liquenoide por enalapril. Reporte de un caso clínico

Silvia Alejandra Serrano García,* Norma Rebeca Rojo Botello,§ Daniel Quezada Rivera^{||}

ABSTRACT

Enalapril is a drug widely used due to its effectiveness in the treatment of blood hypertension cases, nevertheless, it occasionally generates lichenoid reactions as negative effect. The clinical picture of this alteration can be varied, in the skin and/or oral mucosae, it can induce lesions similar to those of lichen planus. These lesions could be the result of hypersensitivity reactions of a body which is susceptible to this drug. The present article documents the case of a 49 year old female patient, who sought consultation due to spontaneous gingival bleeding, bleeding caused by dental brushing, pain, and burning sensation with acid, hot or spicy foods. The condition had been present for the last three years. The patient had been repeatedly treated with antibiotics and anti-fungal drugs; nevertheless, these treatments proved to be unsuccessful. Oral Pathology, Dermatology and Periodontics Departments emitted a multi-disciplinary diagnosis. Oral treatment consisted of teaching appropriate oral hygiene techniques along with topical corticoid therapy, and substitution of the drug which induced the lesions.

Key words: Lichenoid reaction, enalapril, allergic and hypersensitivity reactions.

Palabras clave: Reacción liquenoide, enalapril, reacciones alérgicas y de hipersensibilidad.

RESUMEN

El enalapril es un medicamento muy utilizado por su efectividad para el tratamiento de la hipertensión arterial, sin embargo, en algunos casos genera como efecto adverso reacciones liquenoides. El cuadro clínico de esta alteración es variado, manifiesta lesiones similares al liquen plano en piel y/o en mucosa bucal, resultado de una reacción de hipersensibilidad de un organismo susceptible a este medicamento. Presentamos el caso de un paciente femenino de 49 años de edad, quien refiere sangrado gingival espontáneo y al cepillado dental, dolor y ardor con alimentos ácidos, calientes y picantes desde hace tres años, multitratada con antibióticos y antimicóticos sin mejorar la sintomatología. Se diagnostica interdisciplinariamente por el Servicio de Periodoncia, Patología Bucal y Dermatología. El tratamiento bucal consistió en la enseñanza de una correcta higiene bucal junto con terapia corticoidea tópica y cambio del medicamento que provocó las lesiones.

INTRODUCTION

The oral mucosa is a very effective barrier against several deleterious substances which enter through the mouth and harm the body. This humid membrane can be divided into three types: a) lining mucosa which coats the inner side of the lips, cheeks ventral side of the tongue, floor of the mouth, alveolar mucosa and soft palate, b) masticatory mucosa, which encompasses the gums and hard palate and c) specialized mucosa which can be found in the tongue's dorsum.¹

Its normal anatomy can be altered by several internal and external agents. For instance the aspect of the gum is modified by some infections, systemic alterations, hormonal changes, nutritional deficiencies, dermatological alterations, hematopoietic disorders, trauma, drug therapy, and carcinoma. For all the aforementioned reasons, the oral cavity can be considered a basic and essential means of information on the general health of the patient.^{1,2}

Enalapril can be counted among the anti-hypertensive drugs which elicit oral mucosa

alterations. This drug has caused lichenoid reactions in a small number of patients. These rare, scarcely known alterations emerge from a hypersensitivity reaction of a body susceptible to this drug.³ They are associated to different factors: genetics, infections, hormones, addictions, solar radiation and drug interactions.⁴ They appear as lesions which are similar to lesions associated with lichen planus. In the oral mucosa they appear in annular or reticular shape, plate-shaped, or even atrophic, erosive or ulcerated areas. Their most common locations are labial and

* Student, graduated from the National School of Dentistry, National University of Mexico, UNAM.

§ Professor, Periodontics Department, National School of Dentistry, National University of Mexico.

^{||} Oral Pathology Professor, Graduate and Research School, National School of Dentistry, National University of Mexico (UNAM).

buccal mucosa, alveolar mucosa, gums and ventral side of the tongue.

These lesions generally appear months after the enalapril intake, they can cause pain, burning sensation, hypo-salivation and general discomfort. Several dental treatments and any factor irritant to the mucosa, dental plaque for example, can trigger the onset of new lesions.⁵⁻⁹

As well as clinical characteristics, observed histopathological features are the following: focal hyperkeratosis, acanthosis, epithelial atrophy, hydropic degeneration of basal keratinocytes, cytooid bodies, intercellular edema, lymphocyte sub-epithelial inflammatory infiltrate with presence of neutrophils, scarce eosinophils and, sometimes, epithelium separation at the level of the basal membrane.^{7,10,11}

Diagnosis can be established after having ascertained clinical, histological and immunofluorescent data. Treatment consists on substituting enalapril with another hypertensive agent which will not elicit this untoward effect; treatment will equally consist on stressing observance of appropriate oral hygiene, use of topical corticosteroids due to their anti-inflammatory and immuno-suppressor activity, as well as use of anti-histamines in order to decrease symptoms. Evolution time for this type of lesions is very variable and prognosis is generally favorable.^{5,8,12,13}

The purpose of the present article was to present the clinical case of a patient suffering hypertension who had been treated with enalapril for four years. The patient complained of lesions in the oral mucosa, she had been medicated without experiencing symptom improvement. Lesion evolution time had been three years. Moreover, another purpose of the present article was to disclose the benefits of using histopathological and immunofluorescent studies in order to achieve successful diagnosis and finally highlight the importance of consultation with other specialties.

CASE REPORT

The patient was a 49 year old single housewife, born in Minatitlan, Veracruz and residing in Mexico City. The patient reported that for three years she had experienced bright red, bleeding gums. When ingesting acid, hot or spicy food or when tooth brushing, the patient experienced pain and burning sensation. Chronic gingivitis was diagnosed, and the patient was treated with antibiotics and antifungal agents. After treatment, symptoms did not clearly improve.

Patient's familial history revealed diabetic, alcoholic father, deceased, mother afflicted with hypertension,

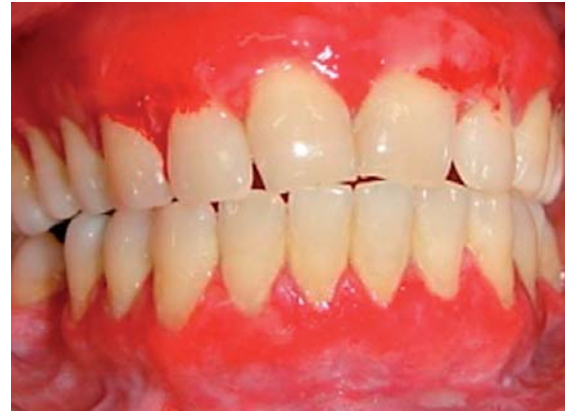

Figure 1. Edematous gingiva with bright red hue and white macules. Alveolar mucosa with white macules. **Color picture in:** www.medigraphic.com/facultadodontologiaunam

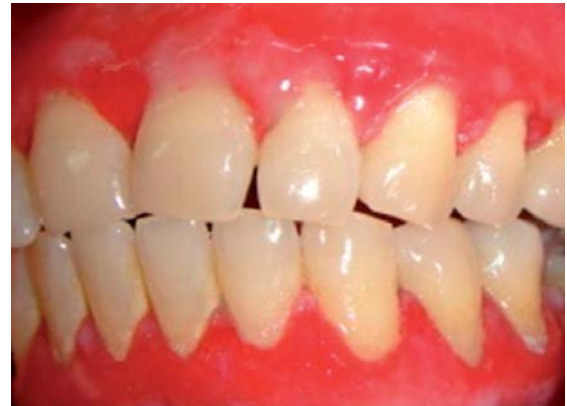

Figure 2. Swollen vestibular oral mucosa with presence of white macules. **Color picture in:** www.medigraphic.com/facultadodontologiaunam

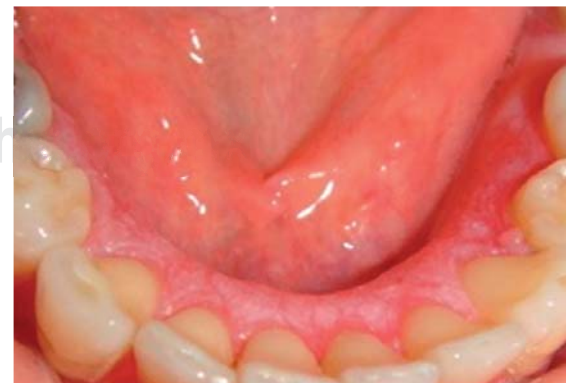

Figure 3. Lingual mucosa with white macules. **Color picture in:** www.medigraphic.com/facultadodontologiaunam

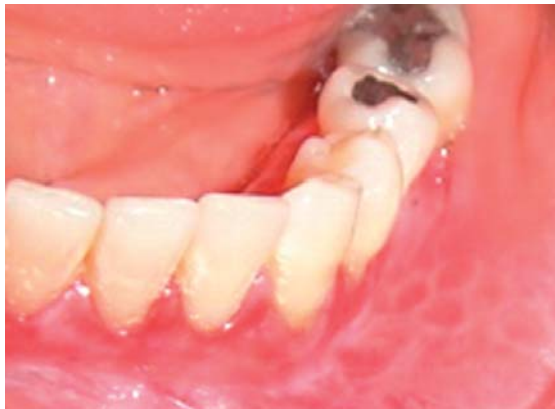

Figure 4. Buccal mucosa with annular-shaped white lesions. Color picture in: www.medigraphic.com/facultadodontologiaunam

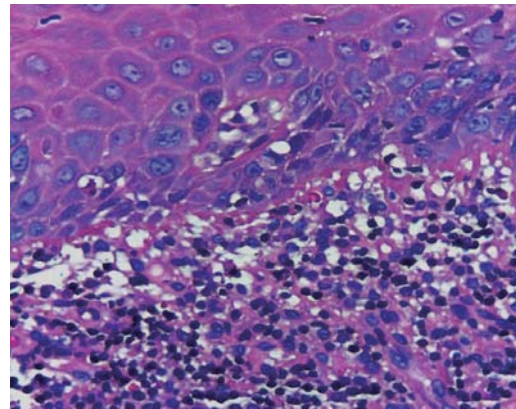


Figure 7. Histological section where the following can be observed: hydroponic degeneration of basal keratinocytes, lymphocyte inflammatory infiltrate and scarce neutrophils. 400x.

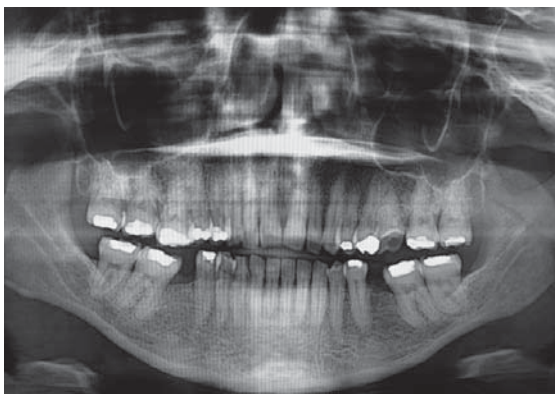

Figure 5. Orthopantomography showing horizontal bone loss in both arches.

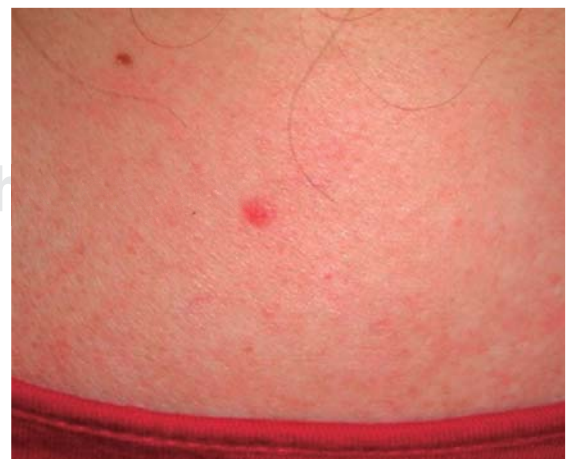
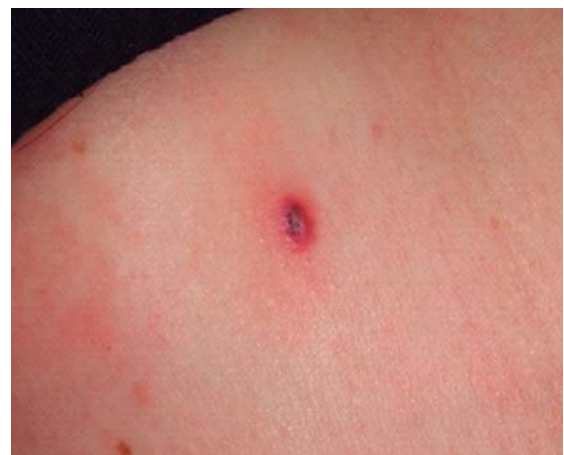
Figure 8. Pustules in high back area.

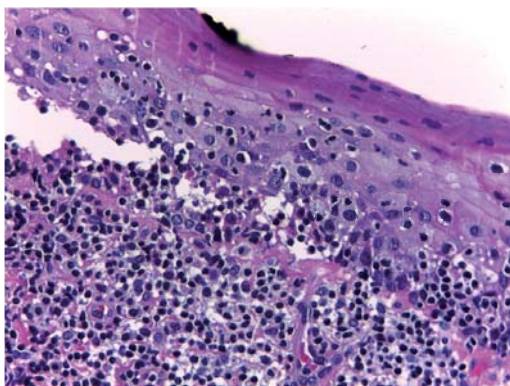


Figure 6. Histological section stained with hematoxylin and eosin. Acanthosis, epithelial separation of conjunctive tissue and sub-epithelial inflammatory infiltrate with lymphocyte preponderance can be observed. 400x.

trigeminal neuralgia, venous insufficiency, and foot cancer. Her 14 year old son was afflicted with untreated skin vesicles. Patient informed having been afflicted with hypertension for six years. The first year she ingested ibersartan, the second felodipine and enalapril for the four ensuing years. This was due to three changes in treating physician. The patient suffered allergic rhinitis during treatment, smoked a minimum of seven menthol cigarettes a week, was a social drinker and the former year had contracted urinary tract infection which resulted in no complications.

Clinical exploration of the mouth revealed edematous, friable, bright red gums with loss of stippling, spontaneous bleeding and white macules in vestibular, lingual and palatal areas. White macules were observed in the alveolar mucosa, as well as annular lesions in the buccal mucosa which did not shed when touched. Other observations were dental calculus in the lower front sextant, halitosis and 3 and 4 mm insertion loss (Figures 1 to 4). Orthopantomography revealed horizontal bone loss in upper and lower jaws. No other relevant pathological processes were observed (Figure 5).

Two biopsies were taken from areas surrounding the lesions in the masticatory mucosa of the upper incisor area, and from the lining mucosa of the lower premolar area. These areas were selected due to the fact that the teeth presented significant lesions. Examined histological specimens showed hydropic degeneration of basal keratinocytes, sub-epithelial blisters and sub-epithelial inflammatory infiltrate of lymphocytes and neutrophils (Figures 6 and 7). A direct immunofluorescence study was equally conducted IgG, IgM, IgA, C1Q, C3C, fibrinogen, kappa and lambda. The study yielded negative results.

Inter-consultation with the dermatology department was requested the better to assess the patient. Dermatological exploration revealed four one cm diameter pustules, in the high section of the back (Figure 8). Skin tests were conducted; no skin shedding was observed, therefore, pemphigoid and pemphigus vulgaris were ruled out as possible diagnoses. Based on an extensive medical history as well as previously conducted tests, emitted diagnosis was enalapril-induced lichenoid reaction. Consulted Periodontics Service determined presence of generalized chronic periodontitis.

Treatment plan consisted on substituting enalapril for another anti-hypertensive agent which would not elicit deleterious effects. Valsartan was prescribed (1.5 tablets every 12 hours) and hydrochlorothiazide (0.5 tablets every 24 hours), as well as loratadine (1

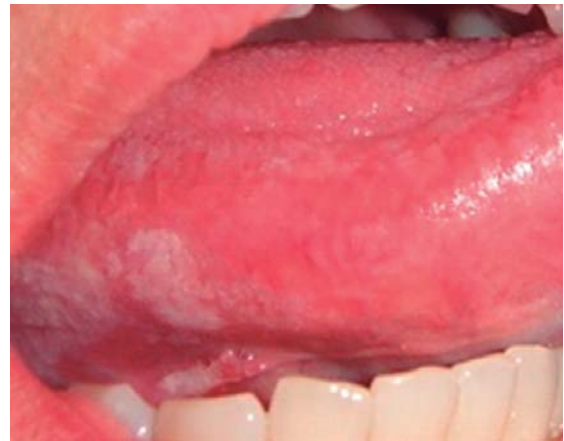

Figure 9. Presence of pseudomembranous *Candida albicans* in mucosa on borders and ventral side of the tongue.

tablet every 12 hours) and oleoderm cream and soap to eliminate symptoms of skin lesions.

0.8 mg solution of mometasone (furoate) was prescribed to treat oral lesions. Indications were to dispense 10 drops of the corticoid into half a glass of water, and rinse for three minutes three times a day after brushing, dosage should be gradually decreased. Periodontal phase 1 was conducted prior to pharmacological treatment. This included personal plaque control, brushing technique, use of interproximal devices and elimination of dental calculus, as well as root scraping and planing in the four quadrants. Twice a day 0.12% chlorhexidine rinses were recommended. Other recommendations were use of dental paste free of additional elements and avoidance of alcohol drinks, and spicy, hot or acid food.

The week following the topical corticosteroid treatment the patient exhibited superinfection due to *Candida albicans* in alveolar mucosa and ventral side of the tongue (Figure 9) therefore, a nistatin suspension mouthwash was prescribed for seven days.

RESULTS

Clear improvement of lesions was observed after three months of recurrent treatment. White macules and striations were disappearing, the gums appeared of a coral-rose hue, free of hemorrhage, pain or burning sensation when ingesting irritant foodstuffs. Insertion loss equally decreased (Figures 10 to 12). The patient was maintained with mometasone (furoate) solution (two drops a day) and she was encouraged to observe appropriate oral hygiene, stressing the importance of brushing and use of

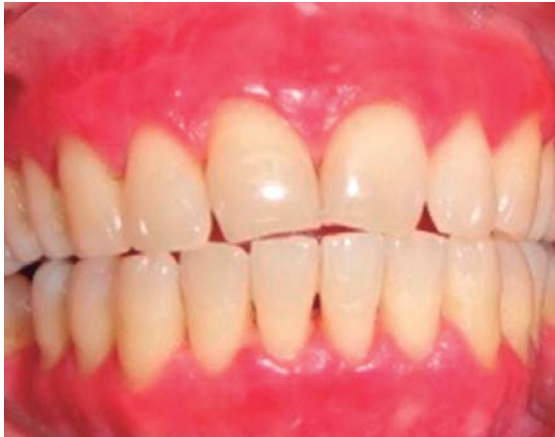

Figure 10. Improvement of oral mucosa lesions.

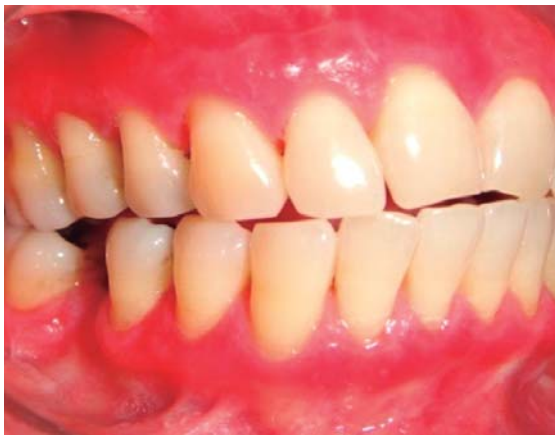

Figure 11. Decrease of white macules in masticatory mucosa. **Color picture in:** www.medigraphic.com/facultadodontologiaunam

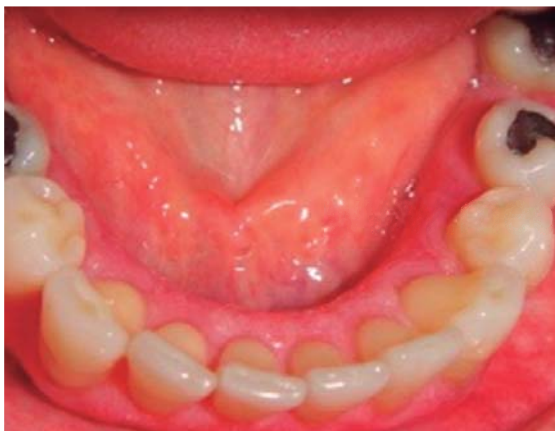

Figure 12. Decrease of white macules in lingual mucosa. **Color picture in:** www.medigraphic.com/facultadodontologiaunam

inter-proximal devices, since this is the key to the improvement in periodontal health and will help in the prevention of lesion exacerbation.

In a joint effort along with the dermatology department, monthly progress of this patient was monitored. It was suggested to the patient to forego tobacco and perform constant self-exploration of mouth and skin, so that, should she observe onset of new lesion she should immediately consult a specialist and request further assessment.

DISCUSSION

Enalapril is a drug constantly used for hypertension, it has renovascular effect and is an adjuvant in cases of congestive cardiac insufficiency. Nevertheless, these afflictions are not often detected or even less related to this anti-hypertensive drug, and this can generate confusion when establishing a diagnosis.¹⁴

Only four cases of enalapril-induced lichenoid reaction have been reported in scientific literature. Dr. Firth⁵ described in his article the fact that lesions were observed in labial, buccal and lingual mucosae. This concurs with findings of the present case, where it was stressed that the gums were the most affected area. In the present case there were equally manifestations in the skin surface of the upper back, this was similar to reports of Dr. Ruiz³ and Dr. Vollenweider⁷ who mentioned that, for their respective cases, lesions of this affliction were observed in the skin. It has been mentioned as a hypothesis that any skin or mucosa surface, including those found in eyes and genitalia, could become affected.

Further study is required to enlighten the subject of secondary reactions caused by enalapril and their consequences in susceptible patients; variations found especially with respect to lichenoid reactions are foremost in this endeavor.

All health professionals who prescribe drugs must assume, per force, the responsibility to inform patients on deleterious effects that might arise from these drugs. This is especially true for patients treated with enalapril. Self-exploration (in skin and mouth) should be recommended to these patients and they should be encouraged to attend programmed appointments so as to immediately be assessed in case of onset of any lesion.

CONCLUSIONS

Dentists must stay current with respect to general diseases which might have oral manifestations, as well as negative effects caused by some drugs.

Enalapril-caused lichenoid reaction is a phenomenon not very frequently observed in the dental practice; nevertheless, it deserves special attention since its early diagnosis could prevent manifestations in other body locations, as well as need for lower corticosteroids dosages.

First of all, and with due authorization of the treating physician, use of the causing drug must be discontinued. Topical corticoids must then be prescribed. Inter-consultation with treating specialists is also recommended, and finally, formalized follow-up of lesions must be observed and careful and periodic periodontal control must be adhered to.

REFERENCES

1. Lindhe J. *Periodontología clínica e implantología odontológicas*. 5a edición. México: Editorial Médica Panamericana; 2010. pp. 3-27.
2. Armitage CG. Development of a classification system for periodontal diseases and conditions. *Ann Periodontol*. 1999; 1 (4): 1-6.
3. Ruiz VR, Blasco MJ, Linares SJ, Serrano OS. Lichen planus-like eruption due to enalapril. *JEADV*. 2003; 17: 601-619.
4. Matesanz PP, Bascones MA. Liquen plano, revisión de la literatura actual. *Av Odonto estomatol*. 2009; 25 (2): 99-114.
5. Firth AN, Reade CP. Angiotensin-converting enzyme inhibitors implicated in oral mucosal lichenoid reactions. *Oral Surg Oral Med Oral Pathol*. 1989; 67: 41-44.
6. Kanwar JA. Photosensitive lichenoid eruption due to enalapril. *Dermatol*. 1993; 187 (80): 1.
7. Vollenweider SR, Mainetti C, Donath R, Saurat JH. Enalapril-induced lichen planus-like eruption. *J Am Acad Dermatol*. 1995; 32 (2): 293-295.
8. Sumairi BI, Satish KS, Rosnah BZ. Oral lichen planus and lichenoid reactions: etiopathogenesis, diagnosis, management and malignant transformation. *JOS*. 2007; 49 (2): 89-106.
9. Gagari E. Desquamative gingivitis as a manifestation of chronic mucocutaneous disease. *JDDG*. 2011; 9: 184-187.
10. Al-Hashimi I, Schifter M, Lockhart BP, Brennan M, Bruce JA, Epstein BJ et al. Oral lichen planus and oral lichenoid lesions: diagnostic and therapeutic considerations. *Oral Surg Oral Med Oral Pathol Oral Radiol Endod*. 2007; 103 (25): 1-12.
11. DeRossi SS, Ciarrocca NK. Lichen planus, lichenoid drug reactions, and lichenoid mucositis. *Dent Clin N Am*. 2005; 49: 77-89.
12. Alonzo L, López CL. Diagnóstico diferencial de reacciones medicamentosas adversas. *Rev Cent Dermatol Pasqua*. 2000; 9 (2): 120-125.
13. Llamas MS, Esparza GG, Moreno LL, Cerero LR. Corticoides: su uso en patología de la mucosa oral. *Med Oral*. 2003; 8: 248-259.
14. Chao CA, Díaz MI, Jiménez LG, Alfonso O, Ávila PJ, Piedra RG. Vigilancia postcomercialización de reacciones adversas asociadas a captopril y enalapril. *Rev Electron Biomed*. 2010; 3: 67-70.

Mailing address:

Silvia Alejandra Serrano García

E-mail: adaluna_13@hotmail.com